

Detection of biopesticide Azadirachtin and analysis of gill tissues of the fish *Glossogobius giuri* using HPCL

Parashivamurthy Mamatha¹ Muniyellappa Ramachandra Mohan^{1*}

¹ Lake Water quality research lab, Department of Zoology, Bangalore University, Bangalore, 560 056, India.

* Author for correspondence: mohanramachandr@gmail.com

Received: 06 May 2014 / Accepted: 14 July 2014 / Published: 27 September 2014

Abstract

The impact of Azadirachtin, a natural biopesticide of neem on the gills of the fish *Glossogobius giuris* and the determination of Azadirachtin in the gill tissue were verified using high performance liquid chromatography (HPLC) under laboratory conditions, for 96 h exposure period of 1.0 ppm concentration of neem oil. The HPLC data indicated that 1.9 ppm of Azadirachtin was observed after four days of exposure to the treatment, whereas no detectable level of Azadirachtin in the gill tissue was observed 90 days after the treatment. The impact of Azadirachtin caused an initial increase of the hyperplasia, vacuolization of mucus cells, telangiectasia (clumping of blood vessels), opercula ventilation rates, and respiratory distress in the gills. Whereas concern to behavioral aspects as erratic swimming was observed.

Key words: HPLC; Azadirachtin; Gills; *Glossogobius giuris*.

Introduction

The pollutants released into the aquatic environment causes several disruptions to aquatic productivity which, according to Warren (1971) results on physiological dysfunctions of aquatic organisms. The use of neem for the control of fish parasites and predators are recognized as an economical approach, however they are highly toxic to the fishes (Rao 2006).

The neem is a potential pest control agent (Martinez 2002; Kreutzweiser et al. 2004) and can control fish predators (Dunkel and Ricilards 1998). It was observed high levels of pesticide residues in the fishes and it interfered in the maintenance of their homeostasis (Barton and Iwama 1991; Wendelaar Bonga 1997).

Studies showed that in neem seed oil (not in neem oil) it produces toxic effect in humans as diarrhea, nausea, vomiting, acidosis etc. These toxic effects might be due to presence of aflatoxin and other toxic compounds present in neem oil. Mechanistic investigations indicated that neem oil uncouples mitochondrial oxidative phosphorylation, thus inhibiting the respiratory chain. It also decreases intra mitochondrial levels of acetyl CoA and acid-soluble CoA esters and reduces the mitochondrial ATP content according to Biswas et al. (2002) in the paper Biological activities and medicinal properties of neem. While in the case of neem oil these complications were not noticed.

The most promising natural compound is Azadirachtin (AZA), an active compound found in the neem tree (*Azadirachta indica*). It is antiviral, antibacterial and antifungal and is known for 2000 years. Azadirachtin is a secondary metabolite present in the neem and is biodegradable; it degrades within 100 h when exposed to light and water. It is generally mixed (7.8 ml/l of water) when used as a pesticide (Isman et al. 1990; Harikrishnan et al. 2003).

Fish is the only organism that contains all the essential amino-acids in right proportion. The majority of population

is poor and depends of fish to obtain proteins, as they are available at reasonable price. The *Glossogobius giuris* is a fresh water edible fish, collected from study areas as lakes and rice fields. It is easily available for humans and it is used for feeding.

The HPLC has been used to analyze toxic residues in water as well to analyze residues of treated fish. Bergwerff et al. (2004) used HPLC to analyze residues of malaquita green in *Anguilla anguilla*. Takino et al. (2003) analyzed residues of chloranphenicol in fishes using HPLC method, so as Haug and Hals (2000) for determination of oxytetracyclin in *Salvelinus alpinus*. Dawson et al. (2003) studied chloramines T in *Oncorhynchus mykiss*. Whereas Ingelse et al. (2001) used HPLC method to analyze organophosphates in water samples by direct injection.

The present study analyzed the neem oil impact in fish tissues. Therefore, HPLC method was adopted, to estimate the presence of Azadirachtin residues in fish gills.

Material and methods

Fish sample for histopathology

Samples (*Glossogobius giuris*) fish were collected from the Cauvery delta region of Karnataka, India. Then fishes were acclimatized prior to treatment for 15 days in the laboratory conditions in glass aquaria. The acclimatized fishes were divided into two groups of 10 each. Fishes were exposed for sub lethal concentration of 1.0 ppm of neem oil for four days, short duration and ninety days, longer duration. Fishes were sacrificed periodically and their gills were excised, fixed in Bouin's fluid, decalcified in formic acid and were processed following the standard histological techniques. Tissues were embedded in a paraffin wax of 56-58 degree centigrade and serial section of 4-6 micrometer thickness (Morrison et al. 2007) that was cut, stained in Haematoxylin and counter stained with Eosin (H & E). The sections were examined under light microscopy and microphotographs were taken by using a minisec camera (Cat Cam 35 B: 0.35MP; Microscope eyepiece camera).

Reagents for HPLC

It was used acetonitrile and ethanol (Merck E. Merck), the standard sample for Azadirachtin (Aldrich- Sigma) and monobasic sodium phosphate (Merck). The deionized water was provided by a Milli-Q purification system from Millipore. The chromatographic experiments were carried out in an isocratic high performance liquid chromatographic system, brand Agilent 1,200 series, equipped with a model G1312 binary pump; a UV detector with varied wave length, model G1315c, with wave length adjusted to 217 nm. The sample concentration and the standard solutions were injected in a Thermos C18 column with an auto injector connected to a loop of 20 micron liter. The Thermos C18 column was used. The determination of the Azadirachtin was done in room temperature, with mobile flux adjusted to 0.5 ml/minute. The mobile phase included a mixture of an

aqueous solution of monobasic sodium phosphate (0.05 mol L) and acetonitrile (63: 37 v/v).

Preparation of the analytic curve

The standard solutions of Azadirachtin, in concentrations ranging from 2.4 to 9.9 mg/ml were used to construct the analytic curve. They were prepared by dilution of a standard solution of Azadirachtin. Evaluation of the time of recuperation of Azadirachtin was made using ethanol.

Three whole samples of fish gills weighing 1.5 g were excised and these samples were ground to a homogenous paste. Then was added 20 micron liter of solution of 50×10 micro gram/L of Azadirachtin. The macerate was transferred to a flask and 10 ml of ethanol were added to obtain a final concentration of 250 micro gram/L of Azadirachtin. Then flasks were stirred in a stirring table for 30, 60 and 90 min. The samples were centrifuged for 10 min at 6000 rpm. A volume of 20 micro liter of the floating phase in the HPLC system was injected.

Determination of Azadirachtin in the fish samples

Water samples were collected from Lakes. The concentrations of Azadirachtin ranged from 40.0 to 240.0 micro gram/liter. These samples were diluted in the rate 1:10 aiming to avoid interfering peaks from metabolites present in the samples. Thus 20 microliter of the sample was injected in the HPLC system. During the preparation of the fish samples for the determination of Azadirachtin by HPLC, fish tissue samples (gills) were excised and weighed and underwent maceration in a mortar until a homogeneous mass was obtained. The macerated tissue was transferred to a flask and 10 ml of ethanol was added. The flasks were stirred for 90 minutes in a stirring table. Then the samples were centrifuged for 10 minutes at 6000 rpm. It was injected 20 ml of the 1:10 diluted extract in the HPLC system, according to Abbas and Hayton (1996).

Results

Impact of Azadirachtin on gill tissue of the fish, *Glossogobius giuris*

Histology of gill of fishes without Azadirachtin treatment exhibited no alterations. It could be observed normal appearance of primary and secondary lamellae, skeletal muscles and Cartilagenous rod (Fig. 1). On the other hand, degenerative process was noticed in primary lamella of gill filaments, formation of vacuole in mucus cells, clumping of RBCs, lacunar chloride cells and secondary lamella and eosinophilic cells in *Glossogobius giuris* fish exposed to 1.0 ppm of neem oil for 72 h (Fig. 2). The degeneration and vacuolization of mucus cells were observed when fish was exposed to 1.0 ppm of neem oil for 96 h (Fig. 3). A normal appearance of primary and secondary lamella and fewer changes in the mucus cells were observed in fish exposed to 1.0 ppm concentration of neem oil for 90 d (Fig. 4).

Estimation of the impact of Azadirachtin in the *Glossogobius giuris* fish tissues using chromatographic column method

This study used the chromatographic column Thermos C18 to perform the separation and the determination of the Azadirachtin present in fish tissues.

In the calibration curve (Fig. 5) peaks with the retention time of 21.551, 21.464 and 21.736 min was plotted in the graph, and the areas under the curve to 2.475 ng / micro liter, 4.95 ng / micro liter and 9.9 ng / micro liter were 45.23552, 90.00372 and 182.50537 respectively. The

calibration curve (Fig. 5) drawn from above data passes through the origin. Its correlation co-efficient is 0.99997.

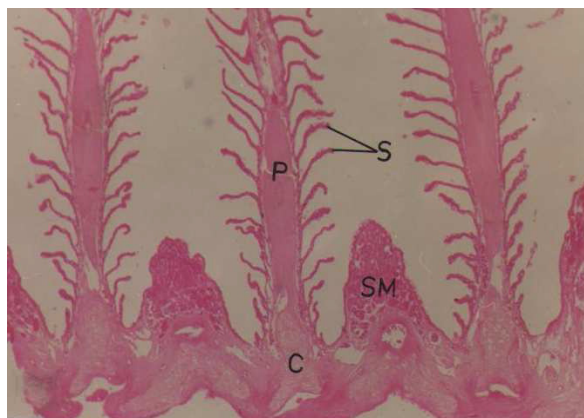


Figure 1. Sagittal section showing gill histology. Normal appearance of primary (P) and secondary lamellae (S), Skeletal muscles (SM) and Cartilagenous rod (C). H & E, 100x.

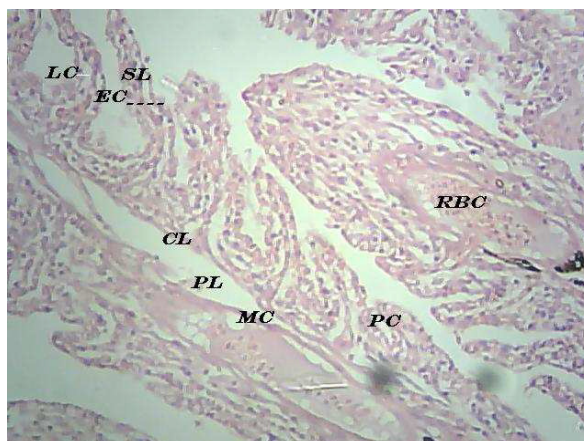


Figure 2. Transverse section of gill filament treated with 1.0 ppm of neem oil for three days (72 h) showing degeneration of primary lamellae (PL), secondary lamellae (SL) and formation of mucus cell vacuolization (MC). Red blood cell (RBC) and eosinophilic cells (EC). H & E, 100x.

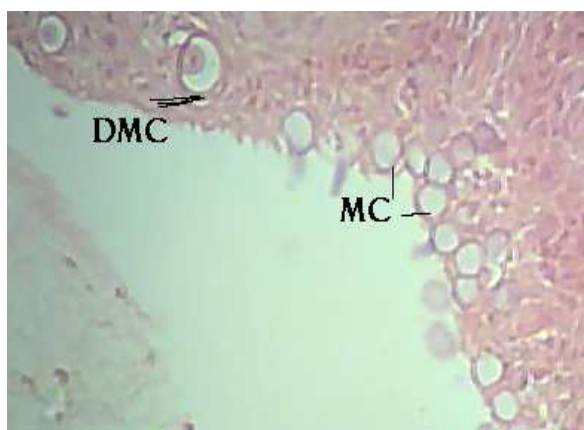


Figure 3. Sagittal section showing gill histology treated with 1.0 ppm of neem oil for four days (96 h) showing formation of mucus cell vacuolization (MC) and Degenerated mucus cell (DMC). H & E, 100x.

It is evident from the Figure 6 that no peak was observed in the blank sample and it could be inferred from the HPLC analysis that the Azadirachtin penetrated into the gill tissues of the fish *Glossogobius giuris* after four days of exposure to the neem preparation containing 1.9 mcg/g or 1.9 ppm (Fig. 7). On the other hand, after ninety days of exposure it was

not observed detectable levels, then, no peak was observed in the Figure 8.

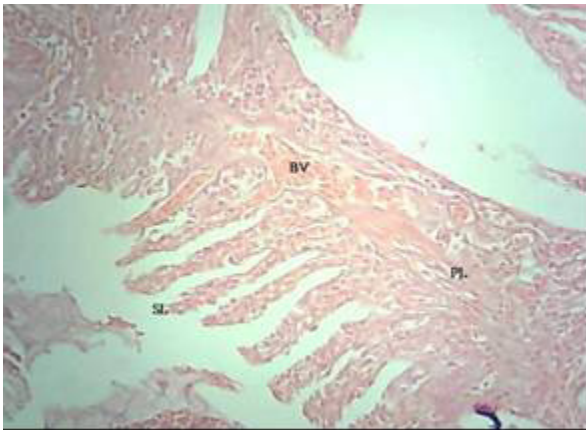


Figure 4. Sagittal section showing gill histology treated with 1.0 ppm of neem oil for 90 d showing fewer changes of mucus (MC), primary lamellae (PL), secondary lamellae (SL) and blood vessel (BV).

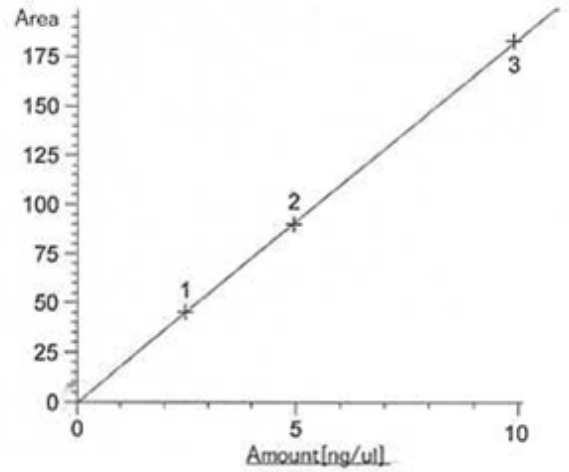


Figure 5. The calibration curve. The amount of Azadirachtin of (1) 2.475 nanogram / micron liter, (2) 4.95 pangram / micron liter and (3) 9.9ng/micron liter which corresponds to the areas of 45.23552, 90.00372 and 182.50537 respectively.

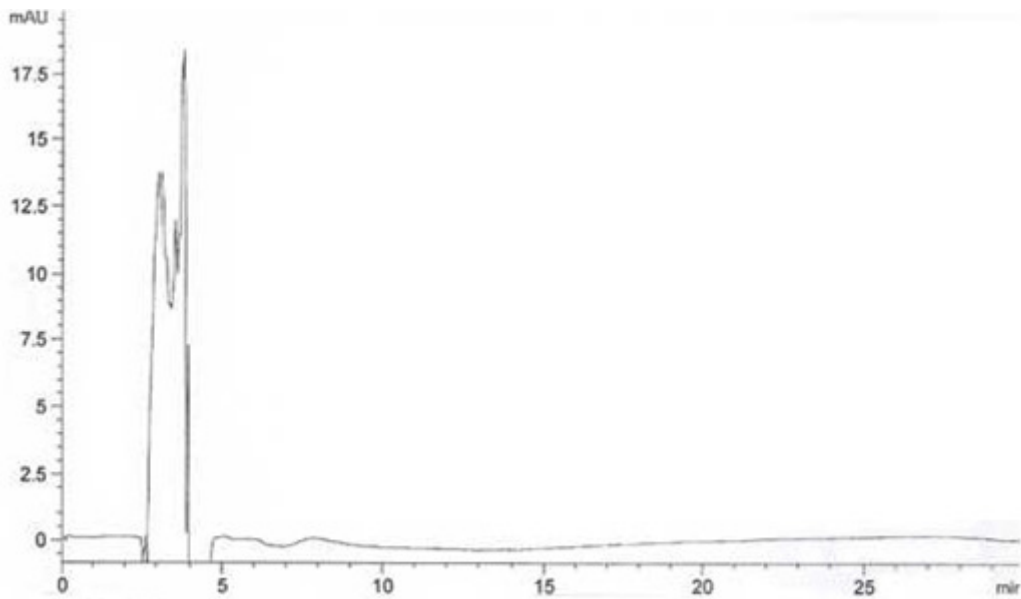


Figure 6. Chromatogram of Azadirachtin in the *Glossogobius giuris* fish gill tissues without Azadirachtin treatment.

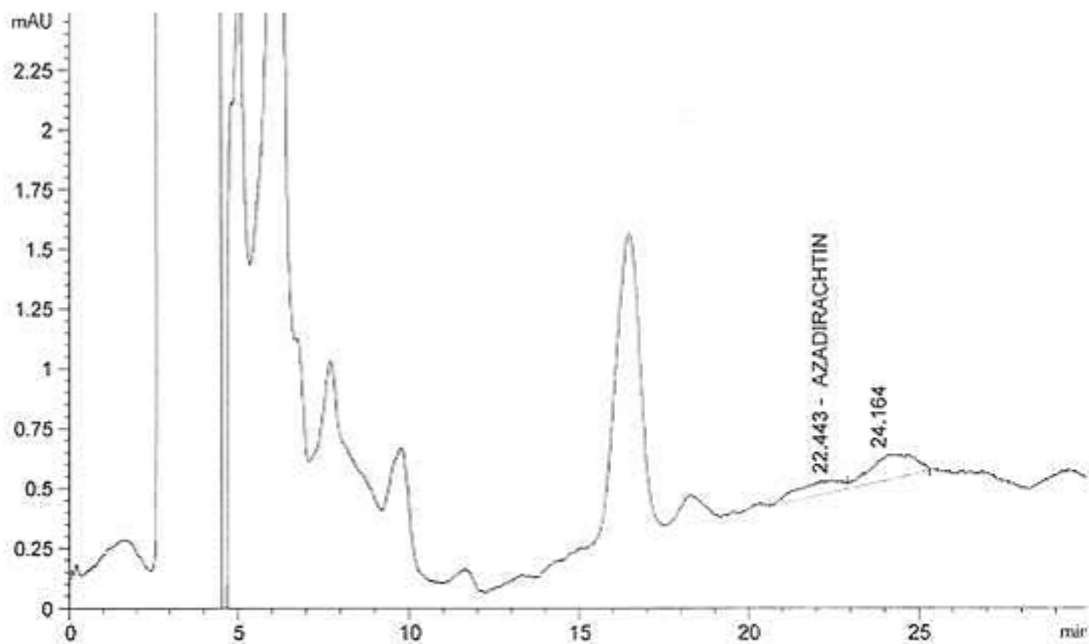


Figure 7. Chromatogram of Azadirachtin in the *Glossogobius giuris* fish gill tissues after 4 days of exposure to 1.0 ppm of neem oil. The chromatogram was obtained after injection of 20 microliter of the gill extract of a sample fish.

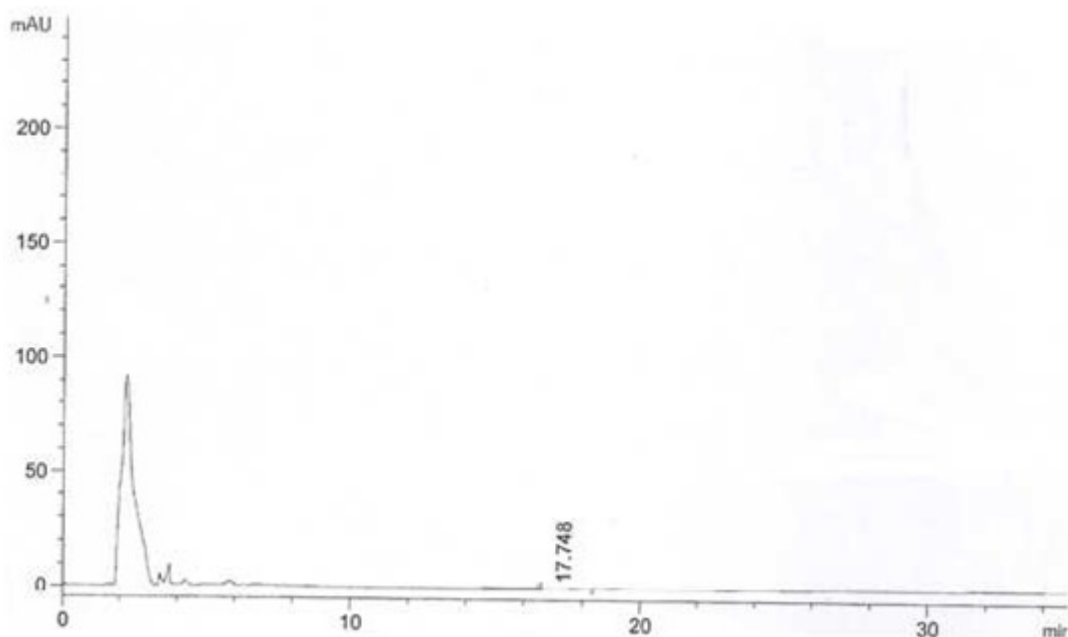


Figure 8. Chromatogram of Azadirachtin in the *Glossogobius giuris* fish tissues after 90 d of exposure to 1.0 ppm concentration of neem oil. The chromatogram was obtained after injection of 20 microliter of the gill extract of a sample fish.

Discussion

The principal constituent of neem oil is Azadirachtin, then, an attempt was made to verify the impact of Azadirachtin in the tissues of the edible *Glossogobius giuris* fish and to estimate the presence of Azadirachtin in gill tissue using HPLC for four and ninety days of exposure.

From the analytical point of view, the preparation of samples of fish tissues is limited by the low polarity of tissues due to the presence of lipids, cholesterol, esters, mono and triglycerides and phospholipids (Hernández et al. 1998) which made the extraction and purification of the sample difficult.

It was observed tissue damage in gills after four days of exposure, including few changes on mucus and a normal appearance of primary and secondary lamellae in the gills with 90 d of exposure to 1.0 ppm of neem oil. It was verified that exposure to Azadirachtin for four days caused initial increase in the hyperplasia, vacuole formation, telangiectasia, opercula ventilation rates, mucus secretion, and respiratory distress in the gills. Behavioural aspects as erratic swimming were noticed (data not shown). This may be due to the fact that the gills of *Glossogobius giuris* fish are highly sensitive to Azadirachtin (1.9 ppm) of neem and it might be causing organ toxicity.

The present study results are in agreement with those observed in the fish *Glossogobius giuris* by Mohan (1996); Sandhyarani (2001) and Mamatha and Mohan (2013).

The HPLC data indicated that 1.9 ppm of Azadirachtin was observed after four days of exposure. It was not observed Azadirachtin in the tissue after exposure to 90 d. The results are in agreement with those observed in other fish species under the influence of different herbicides according to Olurin et al. (2006). Similar results were obtained by several histopathological studies that reported the toxic effect of different kinds of pollutants as heavy metals and pesticides (Hemmaid and Kaldas 1994; Brock 1998; Abraham and Radhakrishnan 2002).

Conclusion

The verification that the neem oil could penetrate the tissues within four days contributes to the tissue damage observed in the histopathological analysis in the gills of the fish *Glossogobius giuris* which is commonly available in rice fields of Cauvery belt area of Mysore.

Short duration residues accumulated may cause health problems to the fish eaters. Longer duration of these residues does not have an impact neither on human nor in the fish itself since Azadirachtin is a secondary metabolite present in the neem and is biodegradable (Isman et al. 1990; Harikrishnan et al. 2003).

It is necessary to have further studies to attribute the tissue damage to the phytoconstituents of the neem oil. The sample size is low; therefore it is necessary to have further studies using higher number of samples.

References

- Abbas R, Hayton WL (1996) Gas chromatographic determination of parathion paraoxon in fish plasma and tissues. *Journal of Analytical Toxicology*, 20(3):151-154.
- Abraham KM, Radhakrishnan T (2002) Study on the gill of field crab, *Paratelpusa hydrodromus* (Herbst) exposed to nickel. *Journal of Environmental Biology*, 23(2):151-155.
- Barton BA, Iwama GK (1991) Physiological changes in fish from stress in aquaculture with emphasis on the response and effects of corticosteroids. *Annual Review of Fish Diseases*, 1:3-26. doi: 10.1016/0959-8030(91)90019-G
- Bergwerff A, Kuiper RV, Scherpenisse P (2004) Persistence of residues of malaquite green in juvenile eels (*Anguilla anguilla*). *Aquaculture*, 233(1/4):55-63. doi: 10.1016/j.aquaculture.2003.11.013
- Brock JA (1998) *Sand Island fish liver disease examinations*. WRRRC Project Report No.PR-98-10.-Water Resources Research Centre, Hawaii.
- Dawson VK, Meinertz JR, Schmidt LJ, Gingerich WH (2003) A simple analytical procedure to replace HPLC for monitoring treatment concentrations of chloramines-T on fish cultures facilities. *Aquaculture*, 217(1/4):61-72. doi: 10.1016/S0044-8486(02)00425-8
- Dunkel FV, Ricilards DC (1998) Effect of an Azadirachtin formulation on six non target aquatic macroinvertebrates. *Environmental Entomology*, 27(3):667-674.
- Harikrishnan R, Rani MN, Balasundaram C (2003) Haematological and biochemical parameters in common carp, *Cyprinus carpio*, following herbal treatment for *Aeromonas hydrophila* infection. *Aquaculture*, 221(1/4):41-50. doi: 10.1016/S0044-8486(03)00023-1
- Haug T, Hals PA (2000) Pharmacokinetics of oxitetracycline of arctic charr (*Salvelinus alpinus* L.) in freshwater at low temperature. *Aquaculture*, 186(3/4):175-191. doi: 10.1016/S0044-8486(99)00376-2
- Hemmaid KZ, Kaldas S (1994) Histopathological and histochemical alterations occur in liver of fishes (*Oreochromis niloticus*) exposed to sublethal concentrations of Ammonia. *Journal of Union of Arab Biologists*, 01A:83-102.
- Hernández F, Serrano R, Pitarch E, López FJ (1998) Automated sample clean-up procedure for organophosphorus pesticides in several aquatic organisms using normal phase to liquid chromatography. *Analytica Chimica Acta*, 374(2/3):215-229. doi: 10.1016/S0003-2670(98)00400-0
- Ingelse BA, van Dam RCJ, Vreeken RJ, Mol HGJ, Steijger OM (2001) Determination of polar organophosphorus pesticides in aqueous sample by direct injection using liquid chromatography-tandem mass spectrometry. *Journal of Chromatography A*, 918(1):67-78. doi: 10.1016/S0021-9673(01)00660-4
- Isman MB, Koul O, Luczynski A, Kaminski J (1990) Insecticidal and antifeedant bioactivities of neem oils and their relationship to azadirachtin content. *Journal of Agriculture and Food Chemistry*, 38(6):1406-1411. doi: 10.1021/jf00096a024
- Biswas K, Chattopadhyay I, Banerjee RK, Bandyopadhyay U (2002) Biological activities and medicinal properties of neem (*Azadirachta indica*). *Current Science*, 82(11):1336-1345.
- Kreutzweiser DP, Back RC, Sutton TM, Pangle KL, Thompson DG (2004) Aquatic mesocosm assessments of a neem (azadirachtin) insecticide at environmentally realistic concentrations-2: zooplankton community responses and recovery. *Ecotoxicology and Environmental Safety*, 59(2):194-204.
- Mamatha P, Mohan MR (2013) Impact of nualgi on histopathological alteration in the gills of fish, *Glossogobius giuris* (ham) brought by neem oil. *Pollution Research Paper*, 32(3):457-465.
- Martinez SS (2002) *O Nim - Azadirachta indica: natureza, usos múltiplos e produção*. Londrina: Instituto Agrônômico do Paraná (IAPAR). 142p.
- Mohan MR (1996) *Studies on the impact of malathion on gastrointestinal system of freshwater Gobiid fish, Glossogobius giuris (HAM)*. Thesis, Bangalore University.
- Morrison CM, Fitzsimmons K, Wright JR (2007) *Atlas of tilapia histology*. US: World Aquaculture Society. 96p.
- Olurin KB, Olojo EAA, Mbaka GO, Akindele AT (2006) Histopathological responses of the gill and liver tissues of *Clarias gariepinus* fingerlings to the herbicide, glyphosate. *African Journal of Biotechnology*, 5(24):2480-2487.
- Rao JV (2006) Sublethal effects of an organophosphorus insecticide (RPR-II) on biochemical parameters of Tilapia, *Oreochromis mossambicus*. *Comparative Biochemistry and Physiology. Toxicology & Pharmacology*, 143(4):492-498.

- Sandhyarani N (2001) *Studies on the effect of pesticide on thyroid and internal gills of freshwater gobiid fish, Glossogobius giuris (HAM)*. Thesis, Bangalore University.
- Takino M, Daishima S, Nakahara T (2003) Determination of chloramphenicol residues in fish meats by liquid chromatography atmospheric pressure photoionization mass spectrometry. *Journal of Chromatography. A*, 1011(1/2):67-75.
- Warren CE (1971) *The biology of water pollution control*. Philadelphia: Saunders Co. 434p.
- Wendelaar Bonga SE (1997) The stress response in fish. *Physiological Reviews*, 77(3):591-625.